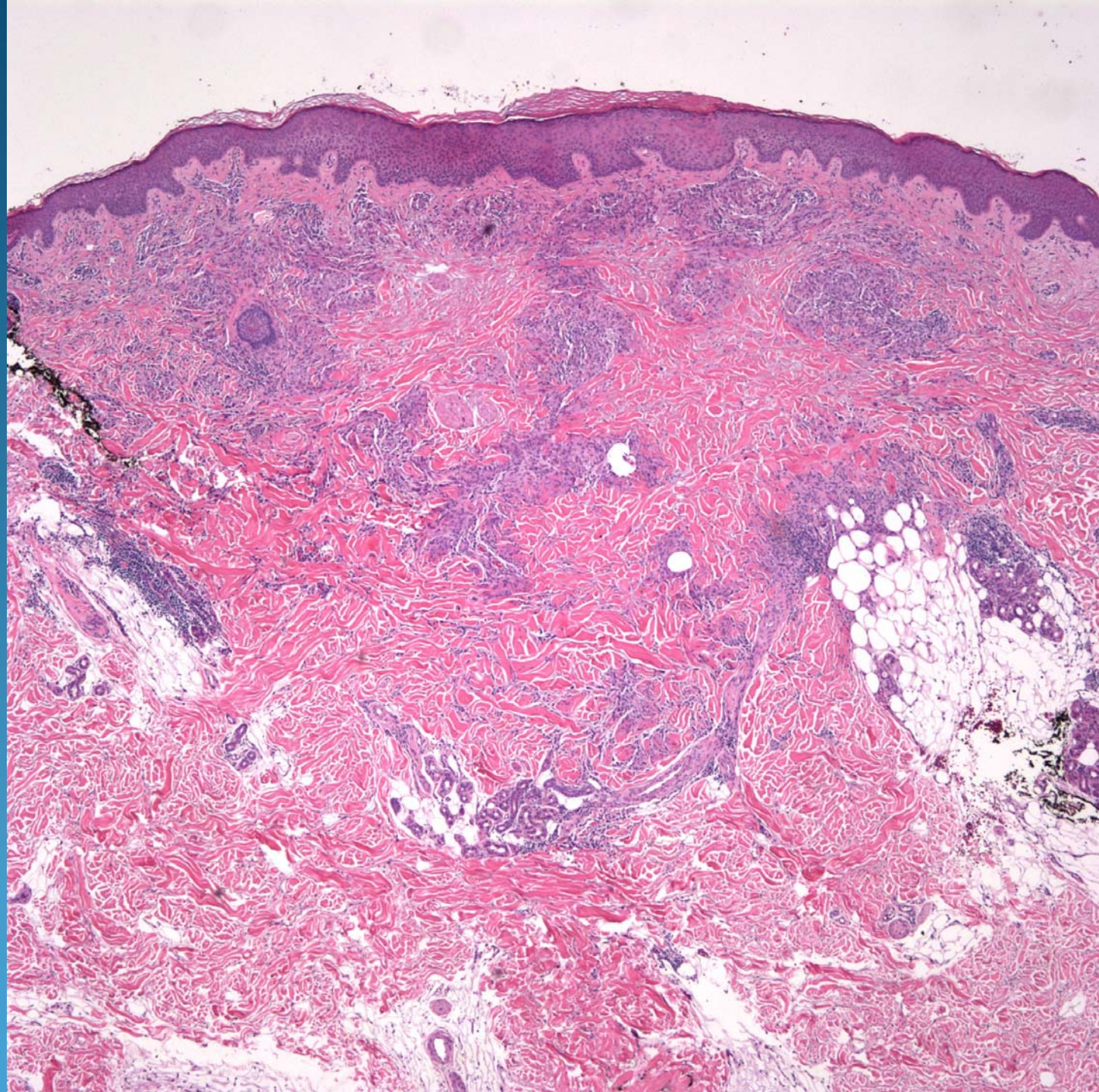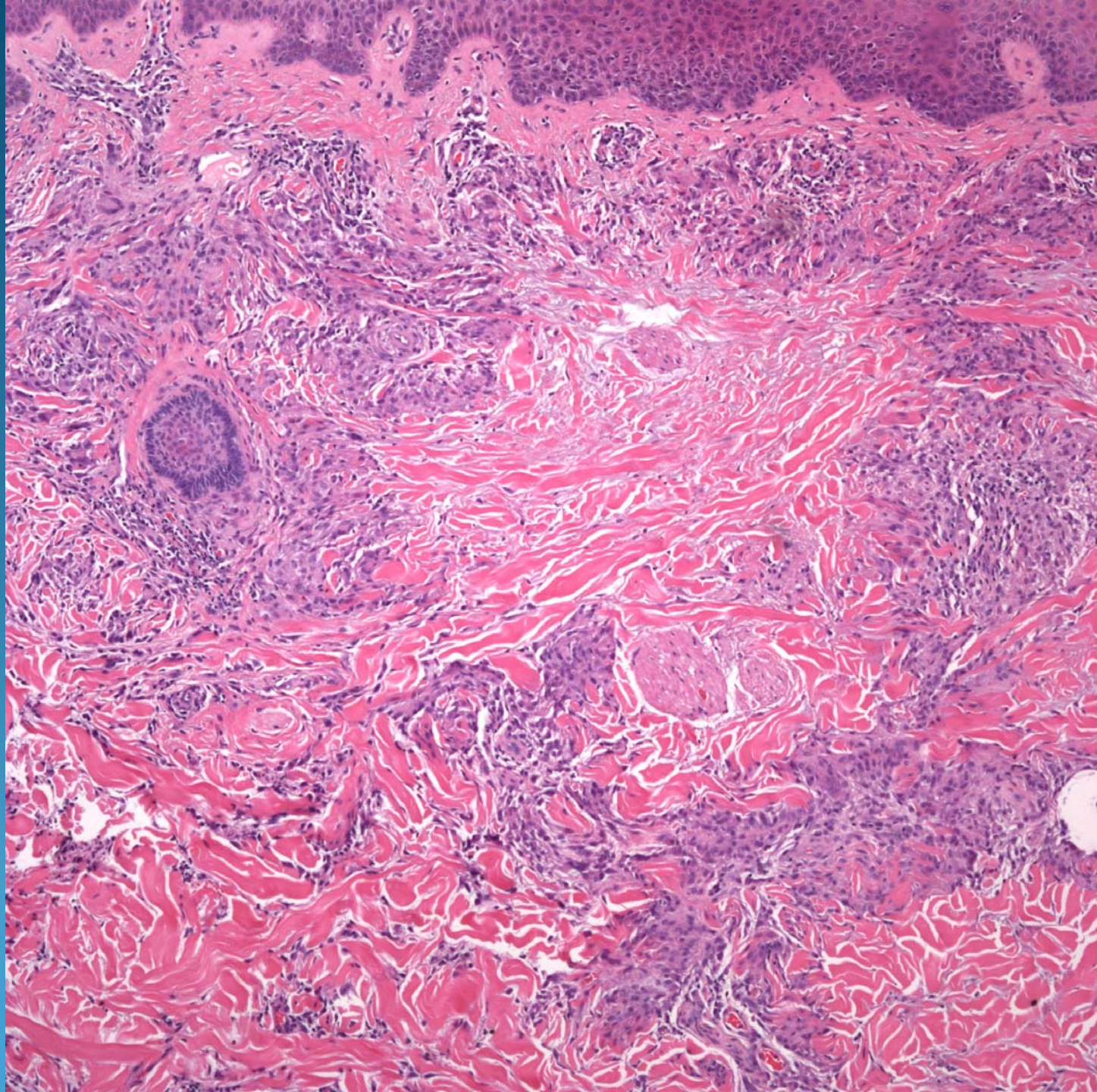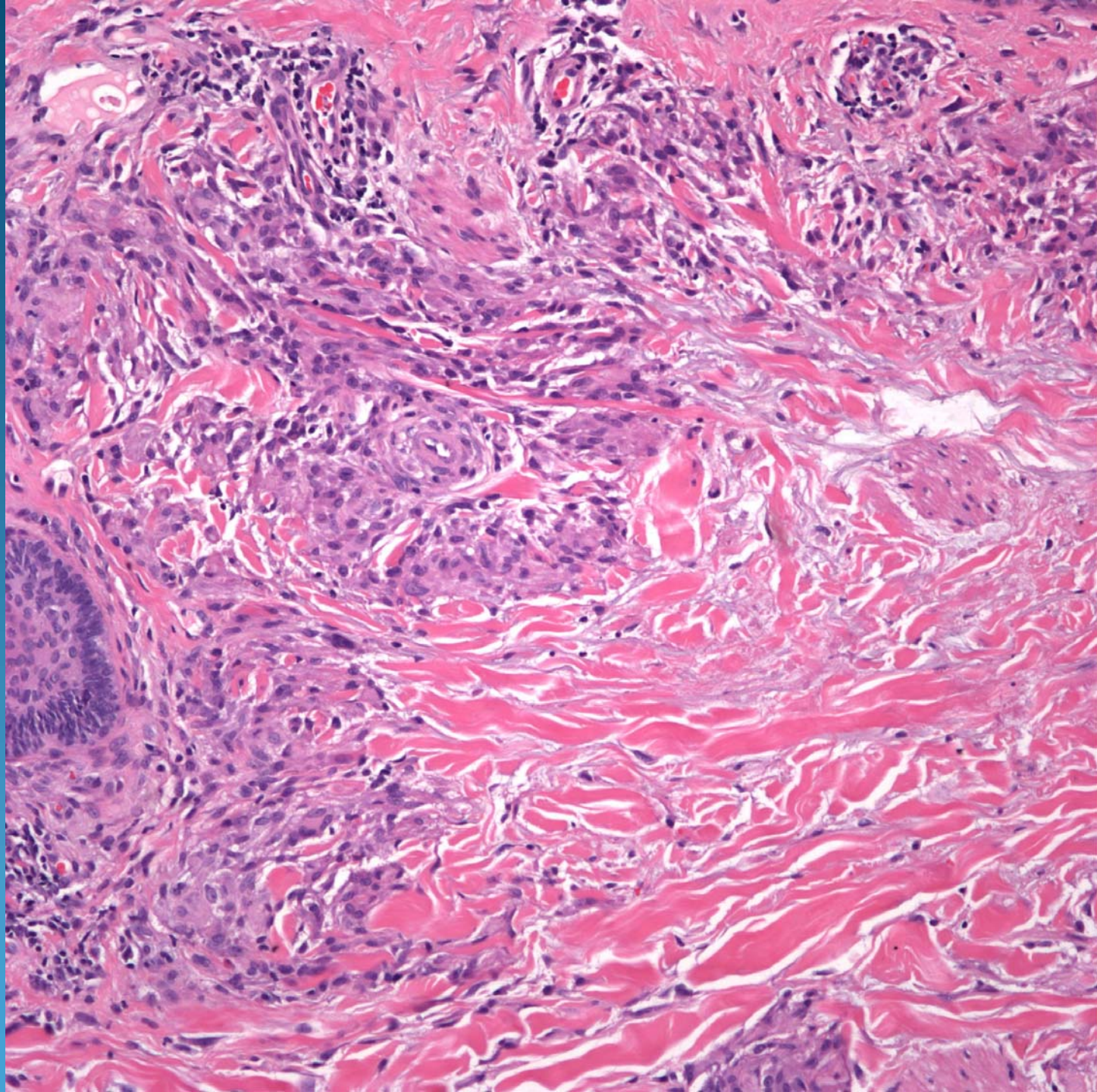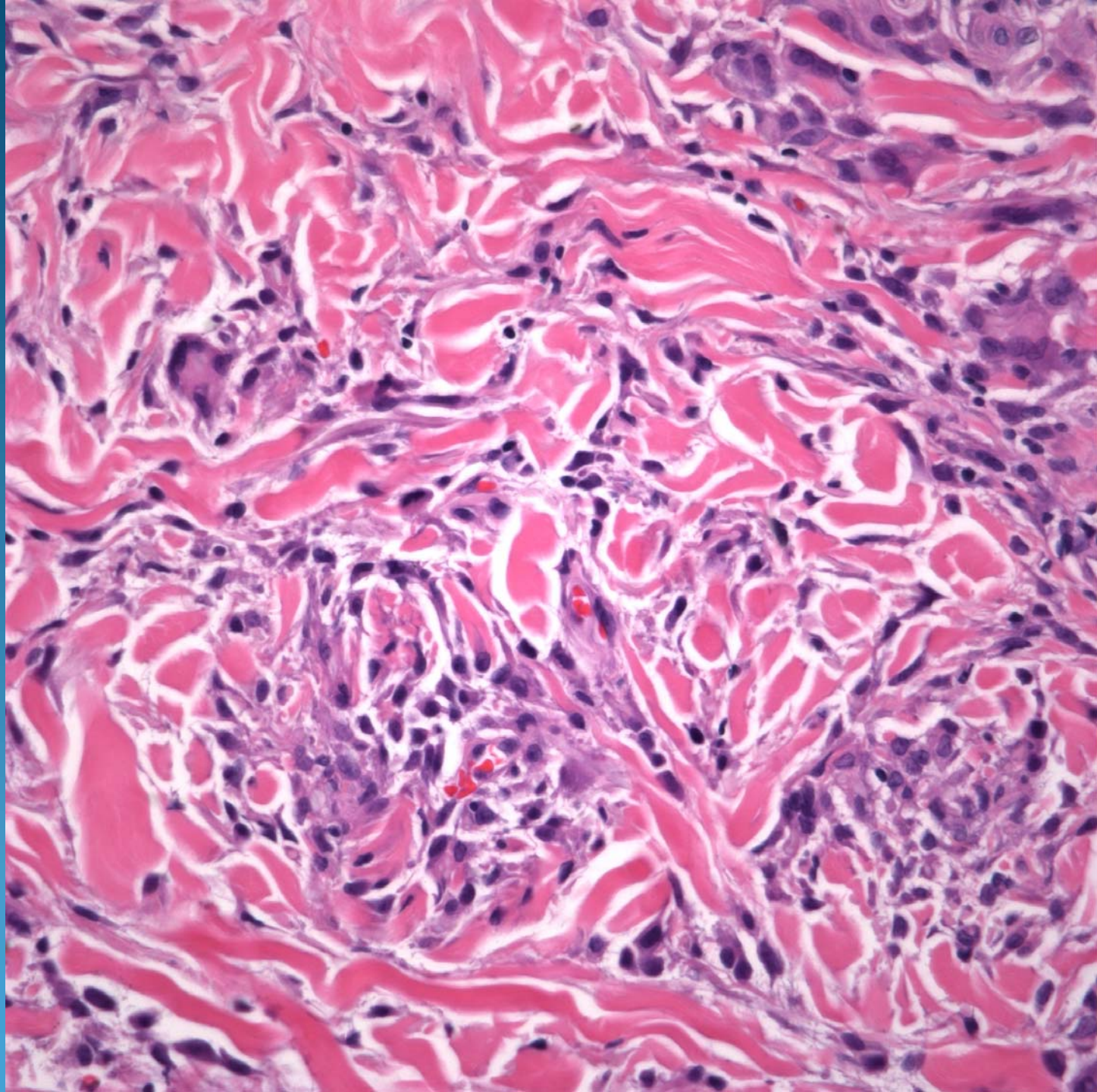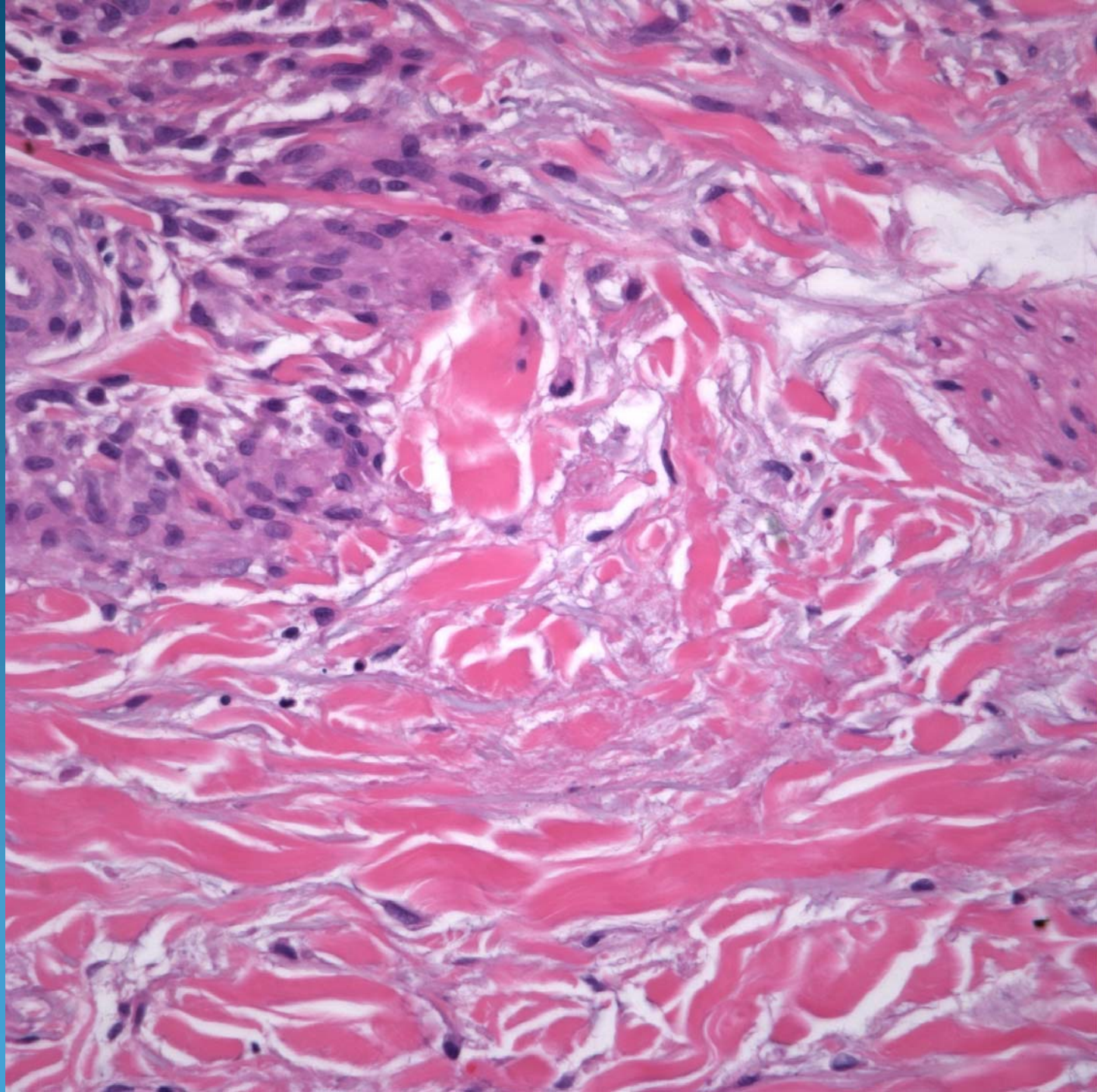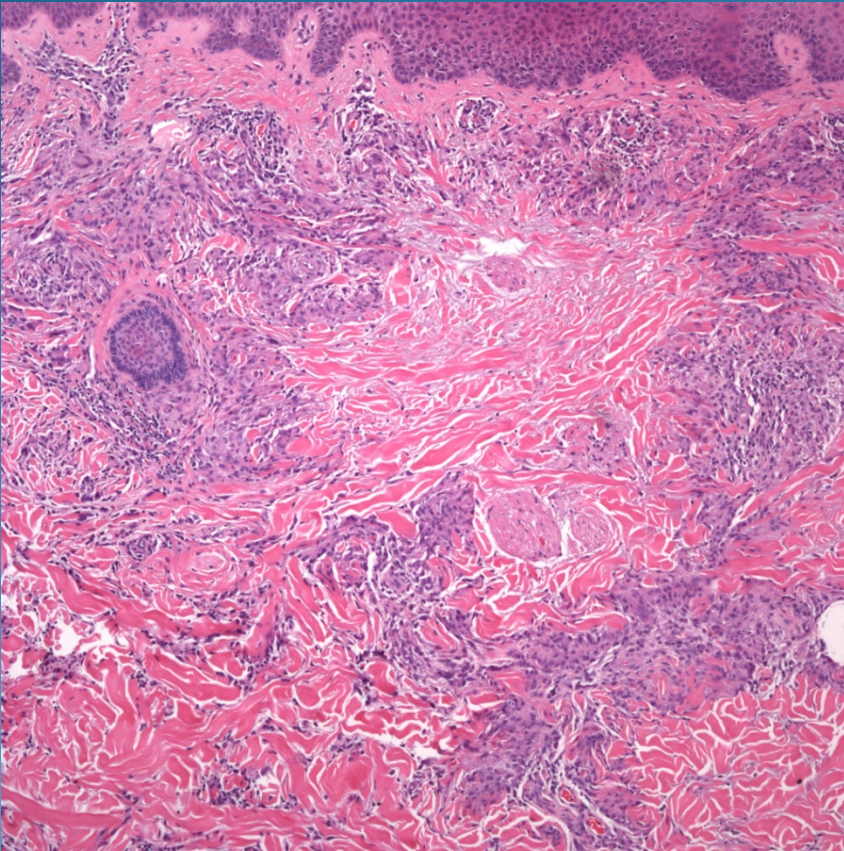


Granuloma Annulare

Pearls



- Interstitial to superficial and deep perivascular and periadnexal lymphocytic infiltrate
- May have rare giant cells
- Infiltrate surrounds areas of necrobiosis with mucin, fibrinoid necrosis, or both